

What's Eating You? Vespids Revisited

Tyler Evans, MD; Dirk M. Elston, MD

PRACTICE POINTS

- Most vespid stings can be managed with nonsteroidal anti-inflammatory drugs, ice, and antihistamines.
- For systemic reactions, prompt recognition and initiation of intramuscular epinephrine is recommended.
- In patients with confirmed allergy, recent data now suggest at least 5 years of venom immunotherapy and potentially lifelong for specific patients.

The Hymenoptera order of insects includes Apidae (bees), Vespidae (wasps, yellow jackets, hornets), and Formicidae (fire ants). All 3 of these families of insects inject venom into their prey or as a defense mechanism via ovipositors in their abdomen. Three types of reactions can be seen after a vespid sting: uncomplicated local reactions, large local reactions, and systemic reactions (SRs). Although many vespid stings can be managed symptomatically, it is imperative for patients and providers to be aware of the possible severe reactions that can take place.

Cutis. 2020;105:17-18.

Identification

The Hymenoptera order of insects includes Apidae (bees), Vespidae (wasps, yellow jackets, hornets), and Formicidae (fire ants). All 3 of these families of insects inject venom into their prey or as a defense mechanism via ovipositors in their abdomen. Vespids are the most aggressive and are found in each of the United States.¹ They have membranous wings, broad antennae, and a nonbarbed stinger (Figure 1).² The nonbarbed stinger of Vespidae differentiates them from Apidae and allows these insects to sting their prey multiple times. Vespids can build nests in the ground (yellow jackets), trees (hornets), or areas of cover such as window shutters (mud wasps). Because only the queens survive winter, larger populations do not develop until late summer when the most stings take place. Stings most often take place near the nest of the vespid or while the victim is eating outdoors.³




FIGURE 1. Vespids. A, The anatomy of a hornet. B, A brilliant image of a yellow jacket. C, A detailed image of a wasp.

Dr. Evans is from the University of Nebraska Medical Center, Omaha. Dr. Elston is from the Department of Dermatology and Dermatologic Surgery, Medical University of South Carolina, Charleston.

The authors report no conflict of interest.

Images are in the public domain.

Correspondence: Dirk M. Elston, MD, Department of Dermatology and Dermatologic Surgery, Medical University of South Carolina, 135 Rutledge Ave, MSC 578, Charleston, SC 29425 (elstond@musc.edu).

Envenomation

When vespids sting their prey they inject venom via their ovipositors.¹ The venom is composed of a mixture of low-molecular-weight proteins, kinins, proteolytic enzymes, lipids, carbohydrates, and high-molecular-weight proteins that act as allergens.^{1,4,5} The proteolytic enzymes degrade the surrounding tissue, basophils become activated, and histamine is released secondary to mast cell degranulation, which results in vasodilation and an inflammatory response characterized by edema, erythema, warmth, and pain.¹ The pain of the sting is immediate and can be intense; almost all victims are acutely aware of the discomforting sensation.⁴

Management of Reactions

Three types of reactions can be seen after a vespid sting: uncomplicated local reactions, large local reactions, and systemic reactions (SRs). The most common reaction is the self-limiting uncomplicated local reaction that includes a focal area of warmth, edema, erythema, induration, and tenderness.¹ Treatment of this kind of reaction is supportive, with ice, nonsteroidal anti-inflammatory drugs, and H₁ and H₂ blockers being commonly used methods. Large local reactions (Figure 2) are similar to uncomplicated local reactions but are greater than 10 cm in diameter and last longer. The same symptomatic treatment may be used along with possible short (3–5 days) oral glucocorticoid (40–60 mg prednisone) or potent topical steroid administration if symptoms persist. Systemic reactions involve IgE-mediated generalized urticaria, angioedema, face swelling, stridor, bronchospasm, nausea, vomiting, flushing, and respiratory distress.¹ Emergency management includes maintenance of airway, breathing, and circulation. Epinephrine injection commonly is employed and should be given via intramuscular injection into the anterolateral thigh; a dose of 0.3 to 0.5 mg can be repeatedly injected every 5 to 15 minutes, as needed.¹

If an individual has an SR, it is recommended to go to an emergency department after stabilization for monitoring. Referral to an allergist for desensitization is appropriate. A radioallergosorbent test to measure allergen-specific IgE can be helpful to confirm an allergy.⁴ This test also should be done weeks after the incident because during the first few days IgE may be too low to measure. Once the allergy is confirmed, the desensitization with venom immunotherapy (VIT) can begin. Venom immunotherapy is effective and reduces a patient's risk for recurrent SRs to less than 5% to 20%.⁶ A 2015 study recommended longer duration of VIT therapy due to risk for repeat SRs after discontinuing therapy. This study concluded that VIT is to be administered for 5 years, unless the patient is at high risk for SRs after VIT therapy—risk factors include older age, cardiopulmonary disease, SR during VIT treatment, mast cell disorders, and elevated serum tryptase—in which case VIT may have to be continued indefinitely. It is recommended that all patients

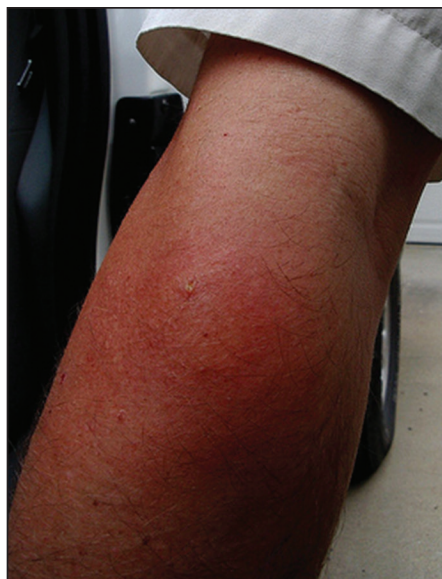

FIGURE 2. A large local reaction after a wasp sting.

with history of SR carry an epinephrine autoinjector in case of emergency.⁶

Epidemiologic data show a prevalence of 0.3% to 7.5% for self-reported SRs due to stings, with lower prevalence in children (0.15%–0.3%).^{4,7} An additional study looking at data from an allergy practice determined 24% of all cases of anaphylaxis were due to insect stings.⁵

Conclusion

Although many vespid stings can be managed symptomatically, it is imperative for patients and providers to be aware of the possible severe reactions that can take place. It is essential for providers to be aware of how to care for and treat large local reactions and SRs, as symptom recognition and timely treatment can improve patient safety and result in better outcomes.

REFERENCES

1. Arif F, Williams M. *Hymenoptera Stings (Bee, Vespids and Ants)*. Treasure Island, FL: StatPearls Publishing LLC; 2019. <https://www.ncbi.nlm.nih.gov/books/NBK518972/>. Updated April 20, 2019. Accessed December 11, 2019.
2. Elston, DM. Life-threatening stings, bites, infestations, and parasitic diseases. *Clin Dermatol*. 2005;23:164-170.
3. Ulrich RM, Gabrielle H, Arthur H. Allergic reactions to stinging and biting insects. In: Rich RR, Fleisher T, Shearer W, et al, eds. *Clinical Immunology: Principles and Practice*. 3rd ed. St. Louis, MO: Mosby/Elsevier; 2008:657-666.
4. Biló BM, Rueff F, Mosbech H, et al. Diagnosis of hymenoptera venom allergy. *Allergy*. 2005;60:1339-1349.
5. Schafer T, Przybilla B. IgE antibodies to hymenoptera venoms in the serum are common in the general population and are related to indication of atopy. *Allergy*. 1996;51:372-377.
6. Ulrich MR, Johannes R. When can immunotherapy for insect sting allergy be stopped? *J Allergy Clin Immunol*. 2015;3:324-328.
7. Abrishami MH, Boyd GK, Settignano GA. Prevalence of bee sting allergy in 2010 girl scouts. *Acta Allergol*. 1971;26:117-120.